International Journal of Paleopathology 17 (2017) 1–9

Contents lists available at ScienceDirect

International Journal of Paleopathology

journal homepage: www.elsevier.com/locate/ijpp

Chronic diseases in cats from the medieval site of Qalhât (Oman)

Hervé Monchot[a,*], Claude Guintard[b]

[a] Labex Resmed, Université Paris Sorbonne, 1 place Victor Cousin, 75005 Paris, France
[b] Ecole Nationale Vétérinaire de Nantes [Oniris]-Anatomie Comparée, route de Gachet, CS 40706, 44307 Nantes Cedex 03, France

ARTICLE INFO

Article history:
Received 3 April 2016
Received in revised form 15 February 2017
Accepted 20 February 2017

Keywords:
Cat
Paleopathology
Bone fracture
Periarticular exostoses
Periodontal diseases
Qalhât (Oman)

ABSTRACT

Paleopathological information observed in cats (*Felis catus*, L. 1758) is rarely described in zooarcheological assemblages. This article is intended to present different bone diseases (infections, degenerative and traumatic lesions) affecting several bones (i.e. femur, hip bone, skull, etc.) of at least two cats from the medieval harbor site of Qalhât (Oman) and to inform us about the health status of these felines.

1. Introduction

Although cats (*Felis catus*, L. 1758) must have been abundant in towns and villages in the Near and Middle East, their bones are generally found in small numbers in zooarcheological assemblages, where most faunal remains represent food debris. Cat bones are most often isolated finds; complete or partial articulated skeletons are rare. Examples include, for instance, 45 bone remains from a kitten at Tell Akkaz in Kuwait (Tomé Carpentier, 2011) or 99 bone remains from a young cat in a late Hellenistic level of the crypt of the church of St. John the Baptist in Jerusalem (Monchot, unpublished results). In most cases cats lived in or near human habitation areas and took advantage of the town as a source of food and shelter. It is therefore difficult to study these feline populations and naturally even more difficult to draw any conclusions about their lifestyle. The discovery of hundreds of cat remains during the archeological excavations of the medieval harbor of Qalhât in Oman is quite exceptional. Among these cat remains, two adult individuals found in the basement of the Great Mosque are particularly interesting. Indeed the presence of numerous lesions on their skeletons allows us to better understand their health status and to make a number of assumptions about the status of the cats living among an Islamic population during the Middle Ages.

2. Material and methods

2.1. The cat material from the Qalhât Great Mosque

Located on the coast of the South Sharqiya province in Oman (Fig. 1), near the easternmost tip of the Arabian Peninsula, Qalhât was a major medieval harbor. The city was founded around 1100 CE. From the 13th to the 15th centuries, it was the second capital of the Hormuz kingdom, which at that time dominated the trade routes in the Arab-Persian Gulf and the western Indian Ocean. It was supposedly devastated by an earthquake at the end of the 15th century, then sacked by the Portuguese in 1508 and eventually totally abandoned in the second half of the 16th century.

Qalhât is mentioned in many medieval sources and was renowned as a major port to India (Rougeulle, 2010). Around the ancient central quarter located on the seaside, an impressive new Friday Mosque was erected along the beach around 1300 CE, within a large architectural complex including wide courtyards and secondary structures. The mosque itself was a very complex and highly decorated building. It was erected on top of a high basement with cellars, into which the prayer hall collapsed when the Portuguese destroyed it in 1508, with almost nothing being left of the superstructures (Rougeulle et al., 2012).

Many cat bones ($n = 492$) were discovered in different buildings on the site. Cistern B2 yielded 103 remains (Monchot and Béarez, 2016), while 52 remains were found in the B94 domestic building, 5 in the B16 “governor” building, 9 in the souk area, 6 in buildings B13 and B95 (unknown function) and 317 remains in the Great Friday Mosque area (Fig. 2). In the latter building, 57 bones were

* Corresponding author.
E-mail addresses: herve.monchot@wanadoo.fr (H. Monchot), claude.guintard@oniris-nantes.fr (C. Guintard).

http://dx.doi.org/10.1016/j.ijpp.2017.02.006
1879-9817/

Fig. 1. Location of the ancient city of Qalhât.

Table 1
Selected cranial and mandibular measurements of Qalhât cats in mm (according to Von den Driesch, 1976).

	Ind 1	Ind 2
Cranium		
Total length (1)	90.8	93.9
Condylo basal length (2)	83.8	88.5
Greatest mastoid breadth (18)	39.4	42.2
Greatest breadth of the occipital condyles (19)	19.1	20.5
Zygomatic breadth (23)	64.7	70.2
Mandible		
Total length (1)	61.8	66.9
Infradental to condyle process (3)	51.8	–
Length of the cheektooth row (5)	18.9	19.4
Height of the vertical ramus (8)	26.3	29.9

identified in different areas of the courtyard, and 260 remains in the various compartments of the basement. Although all parts of the skeleton are present in most cases, isolated bone remains occur in collapse/filling contexts or sometimes in circulation levels.

Cell J of the basement, an ablution room, yielded 127 bone remains (Fig. 3). These bones were found in a disconnected state in a collapse layer. They belong to three individuals, two adults and one kitten represented by one bone, a left mandible with deciduous teeth. In the lower jaw of this juvenile the perforation in the crypt for the M1 is visible indicating that it was 1–4 months of age (Habermehl, 1975; Luff and Moreno-Garcia, 1995). The large size of the skulls and mandibles of the two older individuals (Table 1) and the presence of very marked temporal lines, external sagittal crest and nuchal ridge suggest they were probably two older adult males. The many bone lesions observed in the two sub-complete skeletons of the aforementioned adults will be presented here in order to illustrate the manner in which disease processes affected these two cats.

2.2. X-ray analysis

Each specimen was X-rayed, in lateromedial or dorsoventral views, using a Convix 30 Machine with a Universix 120 command at 43 kV and 4 mA for 17 ms. Images were developed using a Fuji FCR 5000. CT examinations were performed on a 16-slice Computed Tomography manufactured by Siemens (Sensation 16, dedicated to the veterinary environment and industry by Image-Et (Mordelles, France). Helical acquisitions were performed with a collimation High Resolution (HR, 16–0.75 mm) after the Scout View. The constants were 100 kV and 180 mA eff.

3. Results

As it was unfortunately impossible to assign each bone to a specific individual, we chose to present the various pathologies bone by bone. In parallel, all the pathologies described on these two skeletons were summarized in Table 2.

3.1. The postcranial skeleton

The most interesting bone is certainly a healed left femur, which shows a complex mid-diaphyseal spiral fracture (fracture type 32-C1 according to the-Müeller AO guide of classification of fractures, Ruedi et al., 2007) with a periosteal callus consolidation (Fig. 4A1), a displacement of the osseous butts (Fig. 4A–C), and a disappearance of the femoral head replaced by an excavated slip zone presenting a strongly eburnated surface on approximately half of the concavity (Fig. 4A2). The bone is shortened approximately 24% compared to

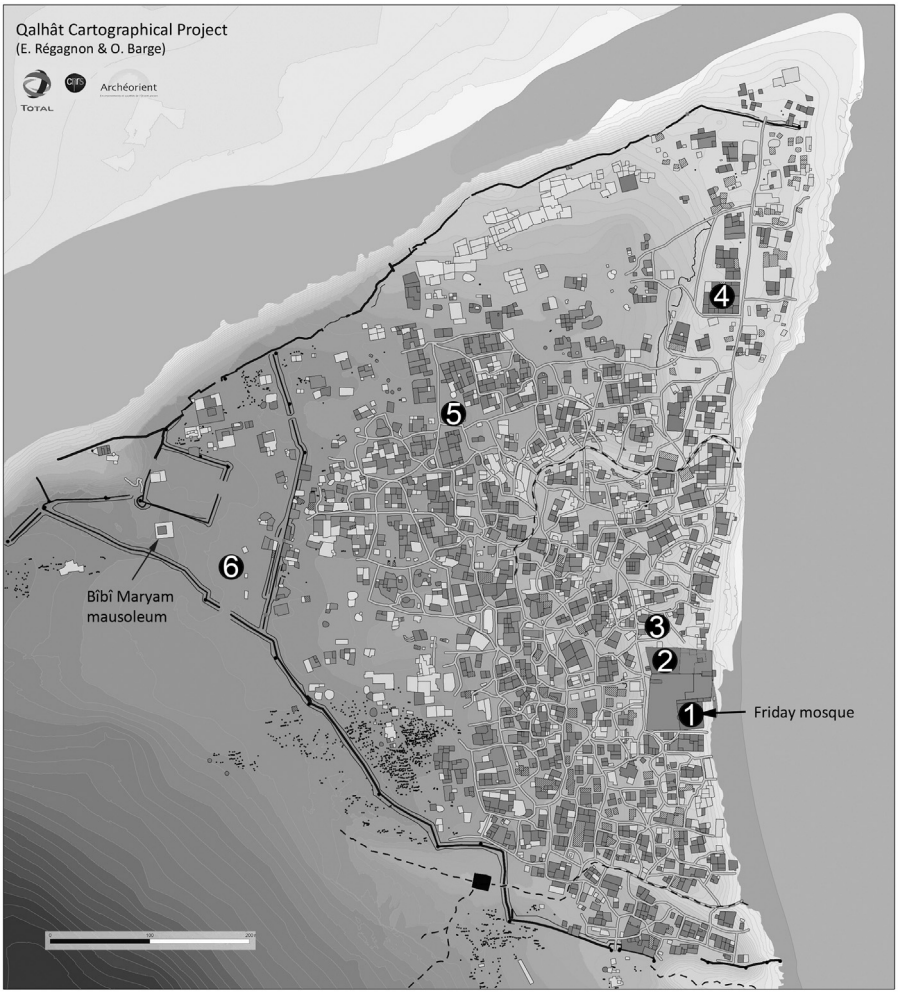

Fig. 2. Cat bone location in Qalhât (1 = the Great Mosque B12; 2 = unknown building function B13/B95; 3 = suq area B140/B141; 4 = the "governor" building B16; 5 = the domestic building B94; 6 = the cistern B2).

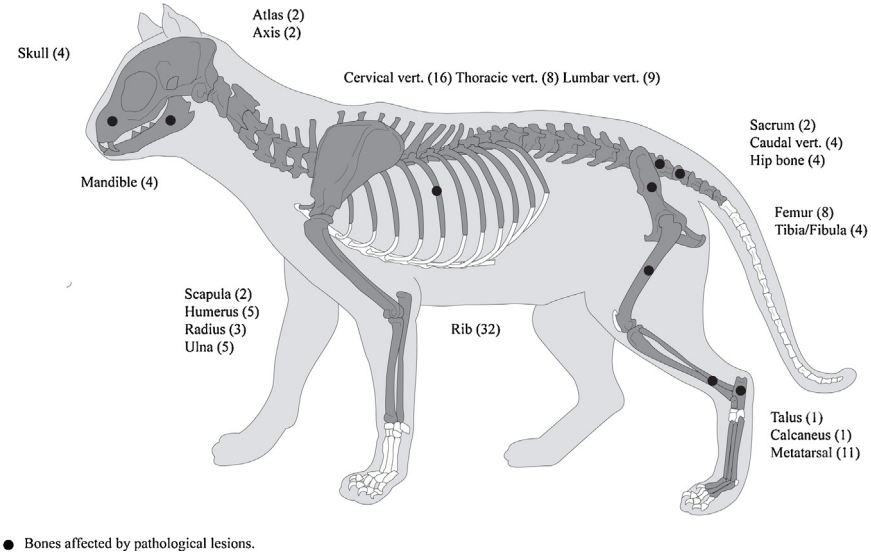

Fig. 3. Skeletal profile in number of identified specimens of cats found in the cell J of the basement of the Great Mosque.

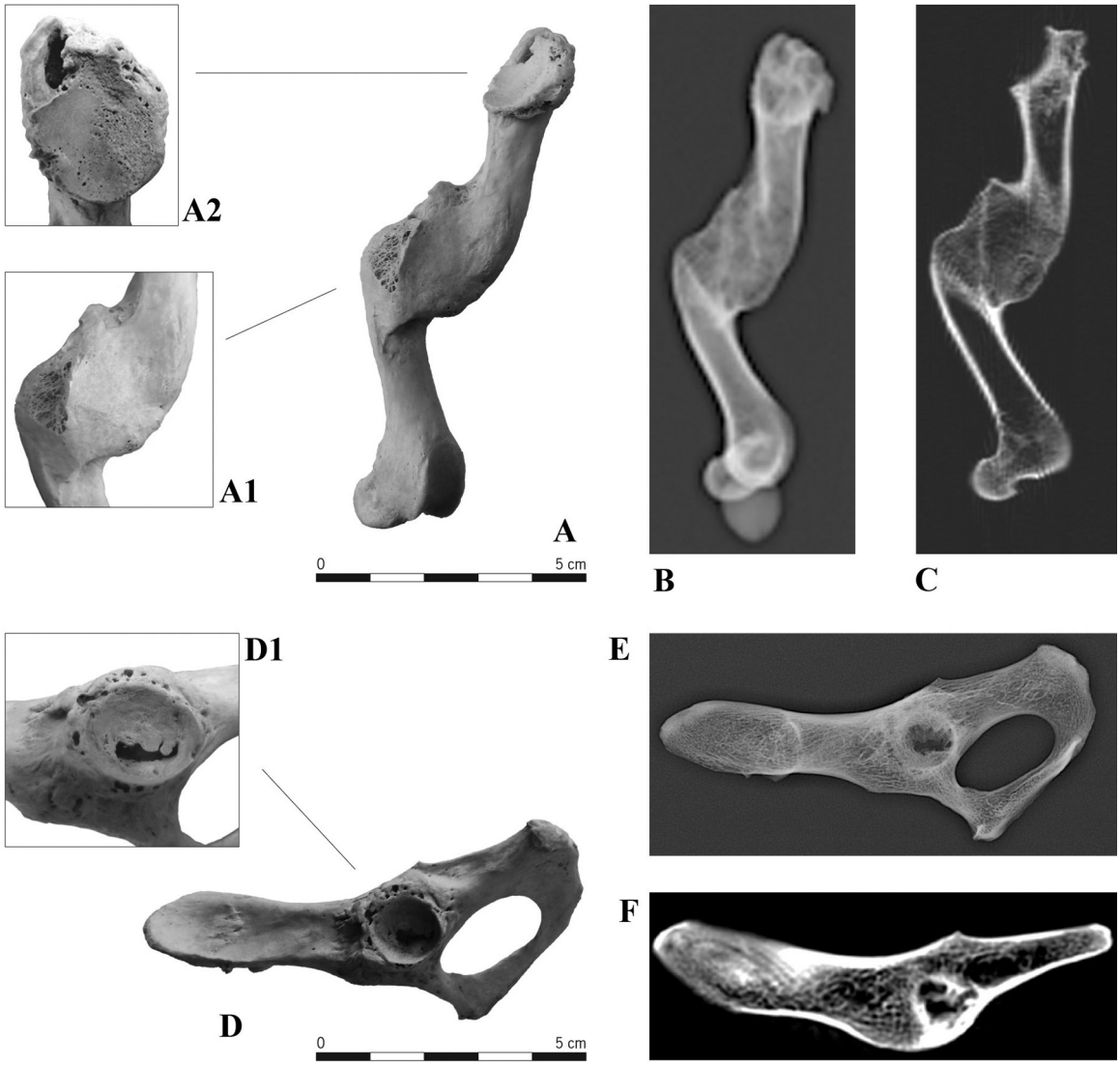

Fig. 4. Cat left femur (A, B, C) and left hip bone (D, E, F) (B12-J-3113). (A): medial view; (A1): bony callus; (A2): proximal extremity; (B): radiography (lateromedial view); (C): CT scanner (sagittal cross section); (D): L lateral view; (D1): acetabulum (lateral view); (E): radiography (lateromedial view); (F): CT scanner (sagittal cross section).

the right femur, and the proximal fragment is displaced about 35° with respect to the longitudinal axis. In this case, it is likely that surrounding muscle mass immobilized the fracture and that spontaneous healing could occur because the animal was rather young when the traumatic event occurred (Udrescu and Van Neer, 2005).

The left hip bone presents a significantly remodeled acetabular area (Fig. 4D–F), at the level of both the cavity (presence of an osseous remodeling with small central exostoses and eburnated dorsal portion of the articular surface [Fig. 4D and D1]) and the acetabular lip, which presents exostoses and a reorganization of osteoclasia/osteoblastic type (osseous deposit as well as presence of small gaps in the form of small openings [Fig. 4D]). The right hip bone presents an ischial bone remodeled at the level of the tabula of the ischium, and the ischial tuber is absent. Right and left hip bones and the femur belong to the same individual, and we observed the presence of a left coxo-femoral neo-joint, without the femoral head.

This neo-articulation evokes chronic hip instability, associated either with a chronic coxo-femoral luxation or with hip dysplasia. Though the latter is well known and abundantly described in dogs, it is a rare condition in cats (Holt, 1978; Patsikas et al., 1998; Keller et al., 1999; Clarke and Bennett, 2006). When it occurs, it is mostly a bilateral complaint that rarely, if ever, results in the complete destruction of the femoral head. This hypothesis must therefore be dismissed in favor of a traumatic dislocation of the femoral head, possibly associated with a fracture of the femoral neck. The detached femoral head may have, as a consequence, become necrotic and have been destroyed, while a functional pseudo-articulation formed between the neck and acetabular border.

For the trunk, the sacrum presents thin exostoses on the right transverse processes of the S2 and S3 vertebrae (Fig. 5A). Among the twenty rib fragments, one rib was fractured and then united, with the presence of a round osseous callus at the level of its ventral quarter (Fig. 5B). The two hip bones (Fig. 5C) of the other individual (the left in two parts) present some exostoses on the ala of the right ilium (Fig. 5D) and on the ischium (Fig. 5C). The left calcaneus exhibits exostoses encompassing the periphery of the bone (Fig. 5E), except for the plantar surface and for the *tuber calcanei* (point of the hock). The articular surfaces are normal. Two tibiae (one right and one left) and two distal extremities of fibulae (one right and one left), which seem to belong to the same individual, all exhibit periarticular exostoses on their distal epiphysis (Fig. 5F). Finally two caudal vertebrae present parrot-beak exostoses, which are vertebral osteophytes, commonly equally referred to as bone

Table 2
Main osseous lesions observed on cat bones and possible origin.

Bone	Traumatic	Degenerative			Infectious
	Fracture	Osseous remodeling	Eburnated surface	Exostoses	
Left femur (Fig. 4A-B-C)	Mid-diaphyseal with callus	Femoral head			
Left hip bone (Fig. 4D-E-F)			Acetabulum		
Right hip bone		Ischium			
Sacrum (Fig. 5A)				Right transverse processes (S2-S3)	
Two caudal vertebrae		Parrot-beaks			
Rib (Fig. 5B)	Round osseous callus at ventral 1/4				
Hip bones (Fig. 5C)				Wing of the right ilium - Ischium	
Left calcaneus (Fig. 5E)				All over the periphery	
Two tibias (R and L) and two fibulae (R and L) (Fig. 5F)				Periarticular (distal epiphysis)	
Skull 1 (Fig. 6A-B-C-E)					Perialveolar osseous remodeling Upper left canine + right P3 and P4 (periodontal disease)
Right mandible (Fig. 6D-F)					Idem for premolar and molar teeth
Skull 1 (Fig. 7)	Lesion on frontal bone				
Skull 2 (Fig. 8A-D)					Inflammatory periodontal disease (3 incisors and 2 canines)
Complete mandible (Fig. 8B-C-E)					Osseous remodeling with filling of dental alveoli - inflammatory periodontal disease

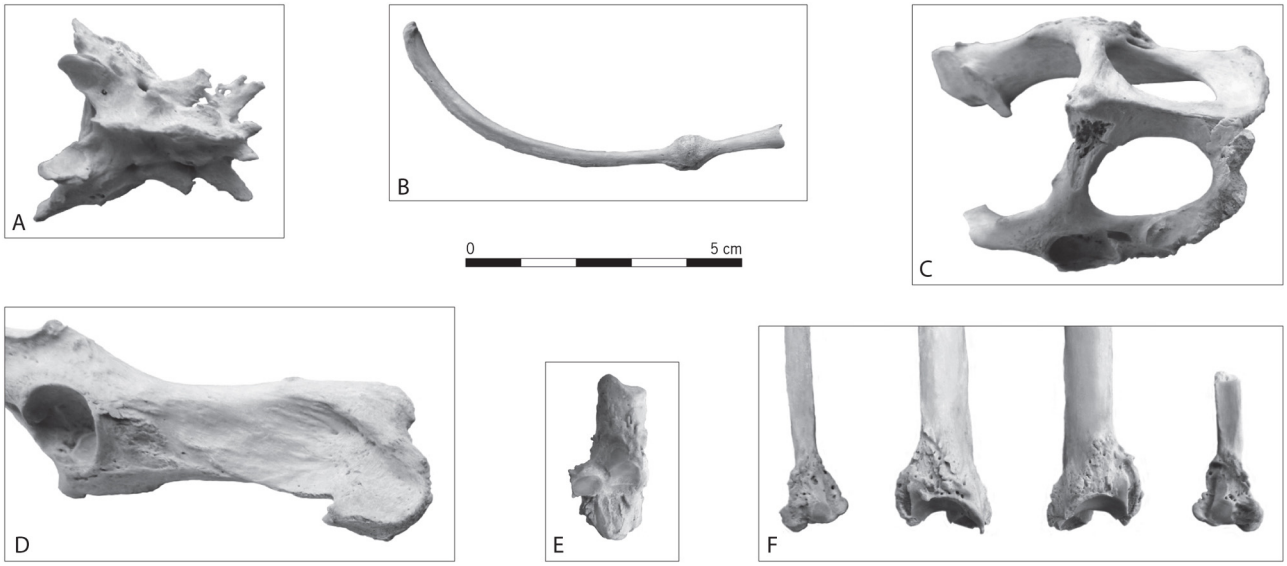

Fig. 5. Cat bones from Qalhât (B12-J-3168. (A): sacrum (dorsal view); (B): rib with round osseous callus; (C): hip bones (ventral view); (D): right hip bone (dorsolateral view); (E): left calcaneus; (F): two tibias (left and right) and two distal extremities of fibulae (left and right).

spurs (Lascelles, 2010). But for some authors enthesophytes would be more appropriate than vertebral osteophytes because degeneration involved an enthesis (Beadman et al., 1964).

3.2. Skulls and mandibles

The cranium of the first individual demonstrates moderate post-depositional altering, most notably on the right zygomatic arch, the left *hamulus pterigoidus*, and the right parietal bone. A post-mortem loss of teeth is also noted, with fracturing or absence of the four upper incisors and of the two upper M1 (Fig. 6A, C). On the left side, the P4 is in place, but its alveoli are remodeled by an apparent periodontal infection; on the right side, both this tooth and the P3 are missing, and their alveoli are sealed by new bone formation. We can also observe a slight osseous remodeling of the dorso-caudal part of the parietal bones on both sides of the external median crest (Fig. 6B) and a perialveolar osseous remodeling, with very brittle bone, opposite the upper left canine alveolus. This canine had been lost ante-mortem, with no sign alveolar remodeling (Fig. 6C, E). The same process took place for the premolar and molar teeth of the right mandible except for the lower right P4, which is still in place (Fig. 6D, F). It is therefore a young adult, which underwent a

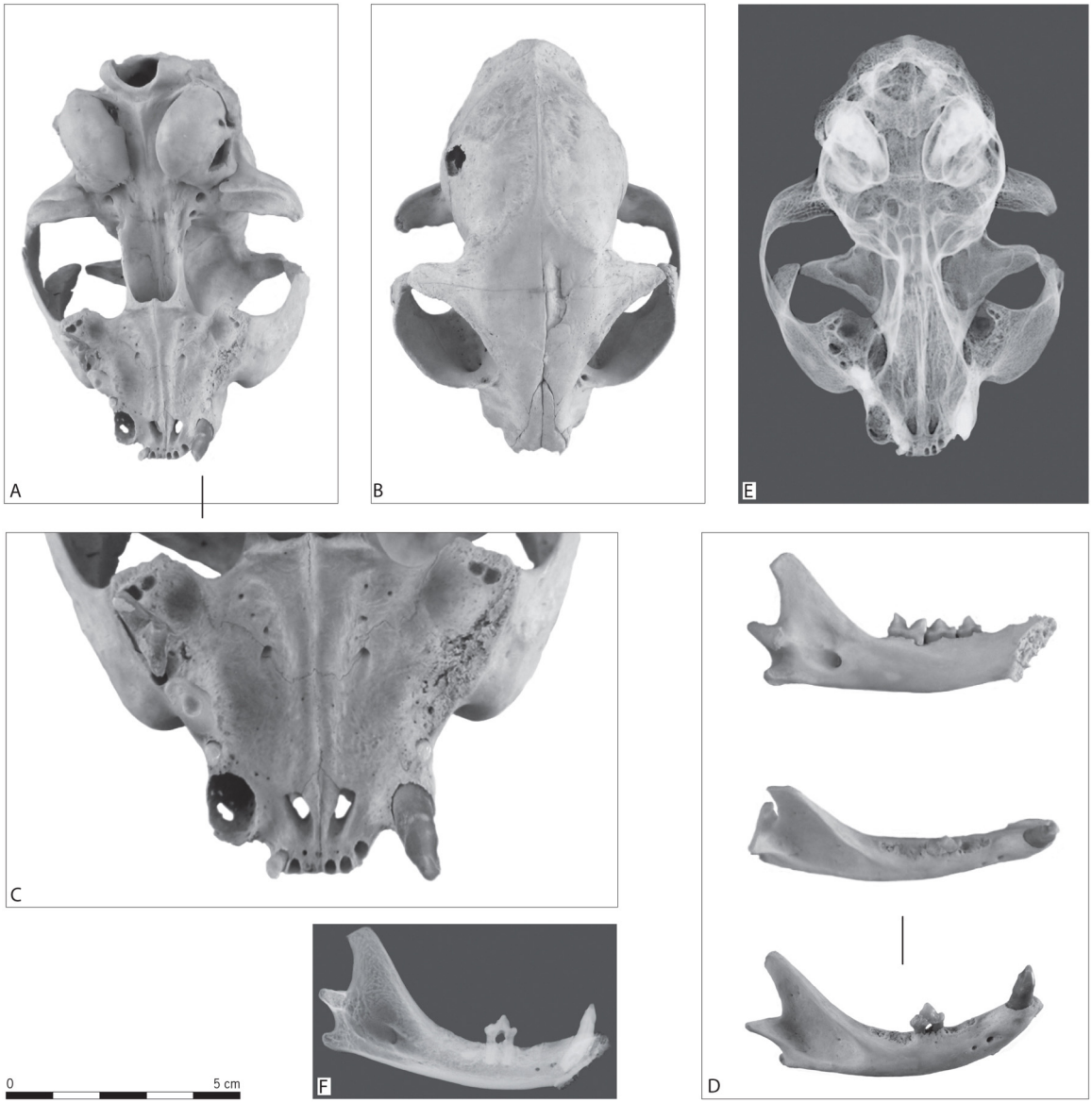

Fig. 6. Cat skull and mandibles from Qalhât (B12-J-3113) (A): skull (ventral view); (B): skull (dorsal view); (C): skull (rostral part in ventral view); (D): right mandible (lateral view); (E): skull (radiography – dorsoventral view); (F): right mandible (radiography – lateromedial view).

series of osseous remodeling and dental losses, due to periodontal disease (Reichart et al., 1984; Colmery and Frost, 1986).

The left frontal bone of the cranium exhibits a traumatic lesion that was in the process of healing at time of death (Fig. 7A). The lesion appears to be a blunt force impact fracture, resulting in a depression of the frontal bone continued by a large osseous fissure running through the parietal in direction of the left temporal, without quite reaching it (Fig. 7B). The lesion was probably caused by a non-fatal blow to the head that occurred not long before death, sufficiently long for healing to begin. Two small bony bridges can be observed on the parietal fissure, and a small callus has formed where it crosses the left temporal line, confirming the nonfatal nature of the injury.

The second skull presents some post-depositional modifications, such as loss of the first upper right incisor, of the upper right P4 and M1 and of three lower incisors and a fracture of the zygomatic process of the temporal bone. The border of the fossa temporalis (*linea temporalis*), the external median crest (*crista sagittalis externa*) and the sharp transverse crest (*Crista nuchae*) are well marked muscular insertions, with united sutures, probably coming from an adult male (Fig. 8A–D). The alveolar surfaces of the two fused mandibles were strongly reshaped with the loss of 3 lower incisors and two lower canines (Fig. 8C). This osseous remodeling with filling of the dental alveoli for the three incisors and the two canines (see radiography Fig. 8E) is consistent with a chronic phenomenon like an inflammatory periodontal disease.

This individual probably has an advanced age, but its teeth are not much abraded; it is not a very old cat. The significant bone remodeling and consequent loss of teeth, however, are chronic phenomena, with filling of major dental alveoli like those of the lower canines, which therefore took place over quite a long period of time (several months or even years).

4. Discussion

In the Great Mosque of Qalhât, these bones belonged to cats that had an altered overall health status and this note constitutes a small contribution to the knowledge of animal bone paleopathology (Harcourt, 1971; Baker and Brothwell, 1980; Mikilikova and Thomas, 2008).

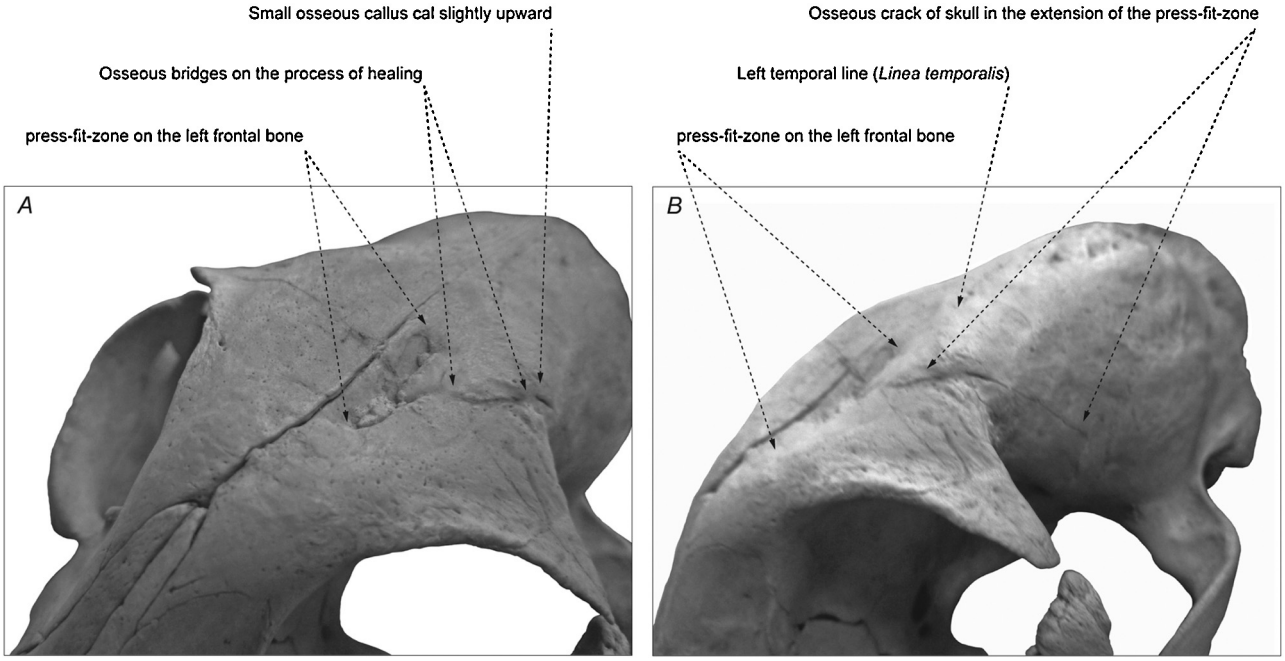

Fig. 7. Cat skull from Qalhât (B12-J-3113): close-up on the press-fit zone on the left frontal bone, (A): skull (dorsal view); (B): skull (lateral view).

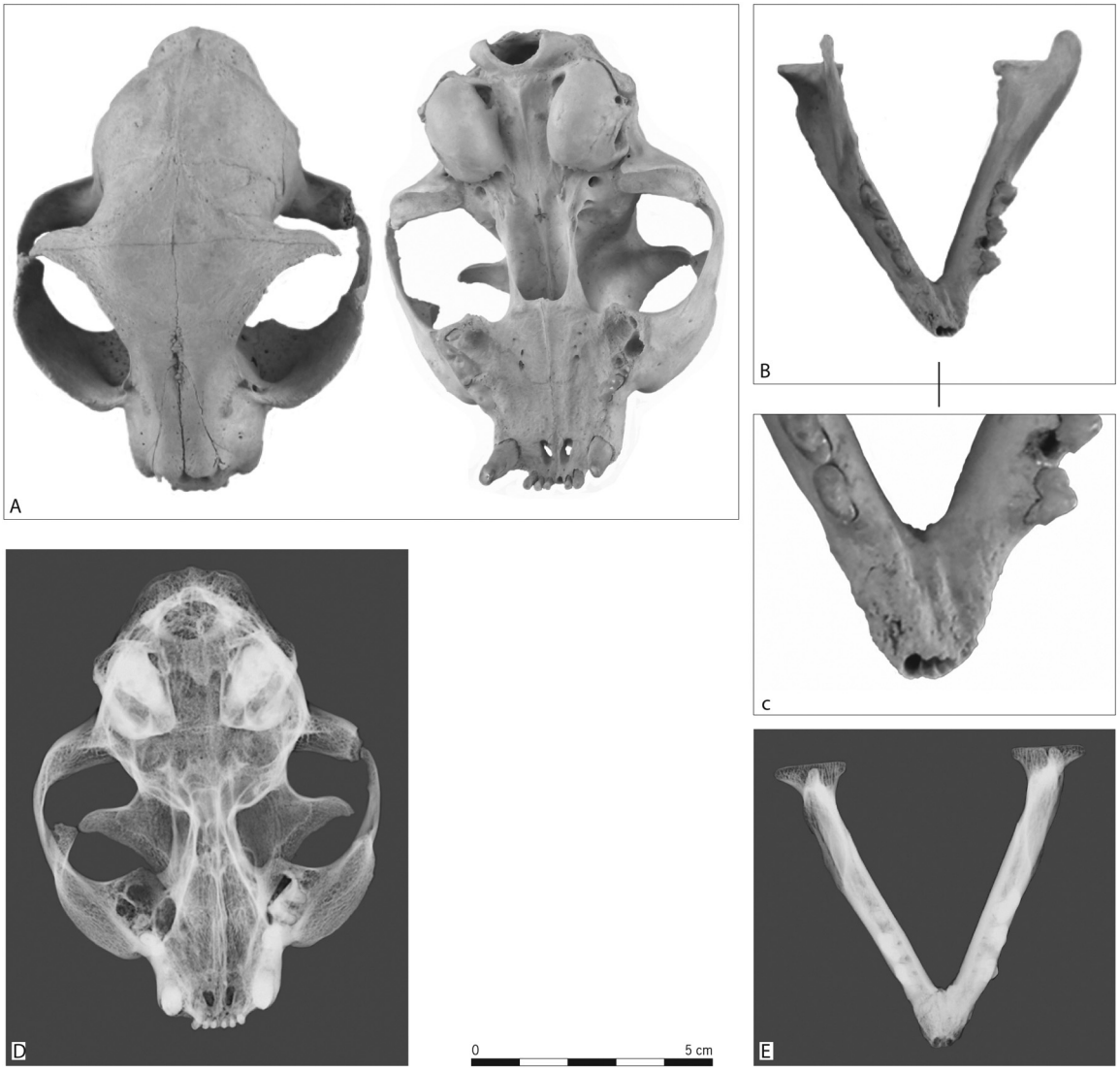

Fig. 8. Second cat skull from Qalhât (B12-J-3113) (A): skull (ventral and dorsal view) and mandibles (dorsal view); (B): skull and mandibles (dorsal view); (C): rostral part of the mandible (rostrodorsal view); (D): skull (radiography – dorsoventral view); (E): mandible (radiography – dorsoventral view).

Among the degenerative conditions regularly observed by veterinarians, osteophytes are often radiological discoveries without any clinical symptoms (Etier-Lafon, 1997), and they are also regularly mentioned in the archeological literature (Harcourt, 1971; Harris, 1977; Warren, 2000). The fracture observed on the femur may have several origins. Indeed, we usually think of cats as graceful and agile animals that can make impressive jumps, but falls, attacks by other animals or human mistreatments can also result in bone fractures. Such a fracture was nevertheless described in a specimen of jungle cat *(Felis chaus)* at Hierakonpolis, a predynastic site in Upper-Egypt (Linseele and Van Neer, 2007, 2008), and in domestic mammals (Udrescu and Van Neer, 2005). A well-healed fracture in an acetabulum, a bony exostosis on a distal femur and a possible myositis ossificans traumatica on an immature proximal femur have been described in various Irish archeological sites (Murphy, 2005).

Regarding orodontal diseases observed on skulls and mandibles, various studies point to the high frequency of these infections (e.g., gingivitis, stomatitis, periodontitis, resorptive lesion, tooth fracture), both in domestic cats and in wild cats (i.e. a diet based on hunting is not a natural protection against oral diseases in the wild cat), and some results clearly showed that periodontitis was more common in older cats (Clarke and Cameron, 1998; Verhaet and Van Wetter, 2004). A mandible showing a cheek tooth loss and alveolar resorption was also described of an Early Modern Age cat from Tizagyenda-Morotva part, eastern Hungary (Gal and Bartosiewicz, 2013).

5. Conclusion

The medieval harbor of Qalhât uniquely presents numerous remains of cats, including many kittens that were found in several places on the site. The high mortality of juveniles observed on the site is not unusual, as young cats were particularly vulnerable as juveniles newly independent of their mothers (O'Connor, 2000). The metaphysial length of the long bones suggests that a majority of kittens were aged 6 months or less (Smith, 1969). No cut marks on cat bones indicative of skinning for the fur or ailurophagy (i.e. consumption of cat flesh) were observed in Qalhât; such alterations have been observed in England (Luff and Moreno-Garcia, 1995) or in Bahrain (Smith, 2005).

Cats obviously lived on the outskirts of human settlements, attracted by garbage, in this case essentially caprine and fish, and were not pets. Unlike dogs, cats are thought to be ritually clean *(tâhir)* in the Islamic tradition, and they are well accepted in homes and even in mosques as they hunt vermin that invade the cities (Bosworth et al., 1998; Walter, 2007). The presence of ten cats (seven adults and three juveniles) found in a small pit in cistern B2 at a time when the latter was abandoned suggests that it served as a garbage dump to get rid of cumbersome corpses present on the site (Monchot and Béarez, 2016). In this context where cats are omnipresent, it is not surprising to find individuals showing various traumatic and infectious symptoms, especially if we take into account their high frequency in the various cat populations. Both pathological individuals were found in an ablution room located under the mosque, accessible only by stairs. Several hypotheses could explain their presence: they were able to take refuge in this room and died *in situ.* As for the cistern, the corpses were probably dumped during a phase of abandonment before the complete destruction of the mosque.

Acknowledgments

The authors are grateful to Axelle Rougeulle (CNRS, UMR 8167) director of the Omani-French research and development project at the harbour of Qalhât (Sultanate of Oman), to Marc Bridou and Jérôme Abadie (ONIRIS, Nantes) for proofreading the English translation, to Christian Raphaël (ONIRIS, Nantes) for taking X-rays, to Cédric Tavernier and Yvan Richaudeau (Mordelles, France) for the CT scans, to Dr. Eric Aguado (ONIRIS, Nantes), to Aurelia Borvon (UMR 7041, Paris I Panthéon-Sorbonne) for their help in cat and dog dysplasia bibliography, to Michel Coutureau (INRAP GSO) for the figure preparation and to Wim Van Neer (Museum Brussels) for his archaeozoological comments.

References

Baker, J., Brothwell, D., 1980. Animal diseases in archaeology. Academic Press, London.
Beadman, R., Smith, R.N., King, A.S., 1964. Vertebral osteophytes in the cat. Vet. Rec. 76, 1005–1007.
Bosworth, C.E., Donzel, E. van, Heinrichs, W.P., Lecomte, G., 1998. Encyclopédie de l'Islam, Nouvelle éd., tome IX, SAN-SZE, ed. Brill, Leiden, article SINNAWR, p. 676–678.
Clarke, D.E., Cameron, A., 1998. Relationship between diet, dental calculus and periodontal disease in domestic and feral cats in Australia. Aust. Vet. 76, 690–693.
Clarke, S.P., Bennett, D., 2006. Feline osteoarthritis: a prospective study of 28 cases. J. Small Anim. Pract. 47, 439–445.
Colmery, B., Frost, D.P., 1986. Periodontal disease: etiology and pathogenesis. Vet. Clin. N. AM-SMALL 16 (5), 817–833.
Etier-Lafon, V., 1997. *Présentation de la paléopathologie animale. Étude de cas.* Thèse de doctorat vétérinaire, Toulouse, 139 p. (unpublished).
Gal, E., Bartosiewicz, L., 2013. Shuffling nags, lame ducks: the archaeology of animal disease. Oxbow books.
Habermehl, K.-H., 1975. Die Altersbestimmung bei Haus- und Labortieren. Verlag Paul Parey, Berlin und Hamburg.
Harcourt, R.A., 1971. The palaeopathology of animal skeletal remains. Vet. Rec. 89, 267–272.
Harris, S., 1977. Spinal Arthritis (*spondylosis deformans*) in the red fox, *Vulpes vulpes*, with some methodology of relevance to zooarchaeology. JAS 4, 183–195.
Holt, P.E., 1978. Hip dysplasia in a cat. J. Small Anim. Pract. 19, 273–276.
Keller, G.G., Reed, A.L., Lattimer, J.C., Corley, E.A., 1999. Hip dysplasia: a feline population study. Vet. Radiol. Ultrasound 40 (4), 460–464.
Lascelles, B.D.X., 2010. Feline degenerative joint disease. Vet. Surg. 39, 2–13.
Linseele, V., Van Neer, W., 2007. Evidence for early car taming in Egypt. JAS 34, 2081–2090.
Linseele, V., Van Neer, W., 2008. Evidence for early car taming in Egypt: a correction. JAS 35, 2672–2673.
Luff, R.M., Moreno-Garcia, M., 1995. Killing cats in the medieval period: an unusual episode in the history of Cambridge, England. Archaeofauna 4, 93–114.
Mikilikova, Z., Thomas, R. (dir.) 2008. Current Research in Animal Palaeopahology. Proceedings of the Second ICAZ Animal Palaeopathology Working Group Conference (Nitra - Slovakia 2004). BAR Int. Series 1844, 98 pp.
Monchot, H., Béarez, P., 2016. Des ossements dans les citernes, Les exemples de Dharih (Jordanie) et de Qalhât (Oman). Syria (93) 339–352.
Murphy, E.M., et al., 2005. Animal palaeopathology in prehistoric and historic Ireland: a review of the evidence. In: Davies, J. (Ed.), Diet and health in past animal populations, Proceedings of the 9th ICAZ Conference. Oxbow Books, Durham, pp. 8–23 (August 2002).
O'connor, T.P., 2000. The archaeology of animal bones. Sutton Publishing, London.
Patsikas, M.N., Papazoglou, L.G., Komninou, A., Dessiris, A.K., Tsimopoulos, G., 1998. Hip dysplasia in the cat: a report of three cases. J. Small Anim. Pract. 39, 290–294.
Reichart, P.A., Dürr, U.M., Triadan, H., Vickendey, G., 1984. Periodontal disease in the domestic cat. J. Periodontal Res. 19 (1), 67–75.
Ruedi, T.P., Buckley, R., Moran, C., 2007. AO Principles fractures of management. Thieme, Stuttgart/New York.
Rougeulle, A., 2010. The Qalhât project. New researches at the medieval harbour site of Qalhât, Oman (2008). PSAS 40, 303–319.
Rougeulle, A., Creissen, T., Bernard, V., 2012. The Great Mosque of Qalhât rediscovered. Main results of the 2008-2010 excavations at Qalhât, Oman. PSAS 42, 341–356.
Smith, R.N., 1969. Fusion of ossification centres in the cat. J. Small Anim. Pract. 10, 523–530.
Smith, I., 2005. The mammal, bird, reptile and molluscs remains. In: Insoll, T. (Ed.), The Land of Enki in the Islamic Era. Pearls, Palms and Religious identity in Bahrain. Kegan Paul, London, New York, Bahrain, pp. 193–231.
Tomé Carpentier, C., 2011. A study of the terrestrial and marine mammals, chelonians and avifauna from Tell Akkaz (Kuwait). In: Tell Akkaz in Kuwait. Maison de l'Orient et de la Méditerranée Jean Pouilloux (TMO 57), Lyon, pp. 319–357.
Udrescu, M., Van Neer, W., et al., 2005. Looking for human therapeutic intervention in the healing of fractures of domestic animals. In: Davies, J. (Ed.), Diet and health in past animal populations, Proceedings of the 9th ICAZ Conference. Oxbow Books, Durham, pp. 24–33 (August 2002).

Verhaet, L., Van Wetter, C., 2004. Survey of oral diseases in cats in Flanders. Vlaams Diergen TIJDS 73, 331–341.
Von den Driesch, A., 1976. A guide to the measurement of animal bones from archaeological sites. Peabody Museum Bulletin 1. Harvard University, Harvard.
Walter, V. 2007. Contribution à l'étude de l'évolution historique du chat: ses relations avec l'homme de l'Antiquité à nos jours. Thèse de doctorat vétérinaire, Toulouse, 137 p. (unpublished).
Warren, D.M., 2000. Palaeopathology of archaic period dogs from the North American Southeast. In: Crockford, S.J. (Ed.), Dogs through time: an archaeological perspective. BAR Int. Series, 889. Archaeopress, Oxford, pp. 105–121.